

Near-Syncope After Exercise

Roy C. Ziegelstein, MD

CASE PRESENTATION

A 72-year-old man complained of near-syncope after exercise that had been occurring for several months. Every morning, he walked at 3.5 mph for about half an hour on his treadmill in the well-ventilated basement of his home. After exercising, he would step off the treadmill, check his pulse, and become lightheaded immediately afterward. This feeling lasted a few minutes and he would then go upstairs to eat breakfast and take his medications.

The patient was referred to me shortly after a very severe episode that almost resulted in loss of consciousness. During that episode, he stepped off the treadmill and tried to feel his pulse as usual. He then felt that he was losing his peripheral vision and thought he would fall. He stopped feeling his pulse and eased himself down to the floor without losing awareness of his surroundings. After a few minutes, he felt better and walked around the room to "cool down."

During the initial evaluation, the patient said that he was otherwise well. He denied headache, difficulty with speech, weakness, chest discomfort, shortness of breath, palpitations, or lightheadedness either during exercise or at other times except immediately after exercise. His medical history was remarkable only for hypertension. Four years earlier, a stress test and echocardiogram, performed as part of a routine cardiovascular evaluation, were both normal. He was regularly taking vitamin E and a combination of hydrochlorothiazide and triamterene. His physical ex-

Syncope and near-syncope are great diagnostic challenges in medicine. On the one hand, the symptom may result from a benign condition and pose little or no threat to health other than that related to falling. On the other hand, syncope or near-syncope can be the manifestation of a serious underlying condition that poses an imminent threat to life. Patients with a cardiac cause of syncope are at far greater risk of dying in the first year after an episode of syncope or near-syncope than individuals with a noncardiac cause. A cardiac cause of syncope should be considered in every patient with syncope or near-syncope, but it is particularly common in older patients or in patients with known structural heart disease, arrhythmia, or certain electrocardiographic abnormalities. Although many diagnostic tests may be helpful in the evaluation of syncope and near-syncope, the history, physical examination, and electrocardiogram pinpoint the cause in many circumstances. Syncope after exercise may be due to left ventricular outflow tract obstruction from aortic stenosis or hypertrophic obstructive cardiomyopathy but can also suggest the diagnosis of postexercise hypotension in which an abnormality in autonomic regulation of vascular tone or heart rate results in vasodilation or bradycardia after moderate-intensity aerobic activity. The patient discussed in this case highlights the importance of the clinical history in the evaluation of this condition, since the diagnosis was revealed as the patient's story was described and eventually acted out.

JAMA. 2004;292:1221-1226

www.jama.com

amination results were entirely unremarkable. Notably, his blood pressure and pulse were normal and there was no significant change in either when he assumed the upright posture. Electrocardiogram results were also normal.

The patient was sent home with a 24-hour ambulatory electrocardiogram (Holter monitor), and plans were made for an exercise treadmill test in the very near future. The patient was asked to perform all his usual activities while wearing the Holter monitor. Specifically, he was asked to exercise on the treadmill in his basement as usual. The Holter monitor recording was completely normal and demonstrated the expected increase in heart rate with exertion. The patient said that he engaged in all his usual activi-

ties during the recording and exercised normally on his treadmill in the morning. He reported that he thought everything was the same that day as always, although he did deviate from his routine slightly and did not take his pulse after exercise because he knew his heart rate was already being monitored electronically. He also noted that he did not experience lightheadedness after exercise on that occasion.

Author Affiliation: Department of Medicine, Division of Cardiology, Johns Hopkins Bayview Medical Center, Johns Hopkins University School of Medicine, Baltimore, Md.

Corresponding Author: Roy C. Ziegelstein, MD, Department of Medicine, Division of Cardiology, Johns Hopkins Bayview Medical Center, 4940 Eastern Ave, Baltimore, MD 21224-2780 (rziegel@jhmi.edu).

Grand Rounds Section Editor: David S. Cooper, MD, Contributing Editor, *JAMA*.

CME available online at
www.jama.com

Box 1. Causes of Syncope**Cardiac or Cardiopulmonary Causes**

Arrhythmias
 Aortic stenosis
 Hypertrophic obstructive cardiomyopathy
 Aortic dissection
 Myocardial ischemia
 Pericardial tamponade
 Pulmonary embolism
 Pulmonary hypertension

Noncardiac Causes

Neurally mediated reflex syndromes
 Vasovagal faint
 Micturition or defecation syncope
 Postprandial hypotension
 Orthostatic hypotension
 Cerebrovascular steal

Conditions Frequently Misdiagnosed as Syncope

Hypoglycemia
 Epilepsy
 Cataplexy
 Vertebrobasilar transient ischemic attacks

Box 2. Electrocardiographic Features Suggesting a Cardiac Cause of Syncope

Atrial fibrillation or flutter
 Multifocal atrial tachycardia
 Paced rhythm
 Frequent premature ventricular contractions
 Ventricular arrhythmia
 Bundle branch block
 Left ventricular hypertrophy
 Pathologic Q waves indicative of prior myocardial infarction
 Mobitz II or higher atrioventricular block
 Wolff-Parkinson-White syndrome

Although I was still concerned about a cardiac cause of near-syncope, one of the leading diagnostic considerations at this point was postexercise hypotension (PEH), a condition in which a patient's blood pressure falls rapidly and significantly after exercise, resulting in lightheadedness or even loss of con-

sciousness. Given the importance of the clinical history in the evaluation of syncope and near-syncope and sensing that a clue was revealed by the absence of symptoms during Holter monitoring, I asked the patient to describe his episodes in detail again and the diagnosis became apparent.

DISCUSSION

Syncope is one of the greatest diagnostic challenges in medicine. While the cause is often benign with no imminent threat to the patient other than that due to physical injury as a result of falling, it is sometimes a sign of a potentially lethal condition such as critical aortic stenosis, hypertrophic obstructive cardiomyopathy, or ventricular tachycardia. Syncope is a sudden loss of consciousness, usually accompanied by falling due to loss of postural tone, with subsequent spontaneous recovery. It is typically due to a transient global decrease in blood flow to the brain for more than 8 to 10 seconds. The inadequate blood flow to the brain is most often caused by systemic hypotension resulting from inadequate vasoconstriction, hypovolemia, decreased venous return, an abrupt change in heart rate, or an acute decrease in cardiac contractility. "Near-syncope" or "presyncope" are terms used when the patient feels as if loss of consciousness is about to occur but does not.

The major causes of syncope are listed in BOX 1 and may be separated into conditions that are primary cardiac or cardiopulmonary and those that are noncardiac.¹ Some conditions are frequently misdiagnosed as syncope (Box 1) since they also produce a temporary disturbance of consciousness that may result in loss of postural tone. Although an individual with one of these conditions may resemble a patient with true syncope, the impaired consciousness in these disorders does not result from sudden transient global cerebral hypoperfusion.¹

One of the first tasks when evaluating someone like this patient is to determine whether there is a cardiac cause of the patient's symptoms. This distinction is important because the 1-year mor-

tality of patients with a cardiac cause of syncope is 2 to 5 times that of patients with noncardiac syncope.^{2,3} In particular, it is important to consider potentially lethal or imminently lethal conditions like ventricular tachycardia, rapid supraventricular tachycardia, torsades de pointes in the setting of congenital or acquired long QT syndrome, myocardial ischemia, or critical aortic stenosis. A cardiac cause of syncope is particularly common in older patients or in patients with structural heart disease, a history of arrhythmia, or who have certain electrocardiographic abnormalities (BOX 2).^{4,5}

Given this, older patients like the 72-year-old man or patients with a history of heart disease should be considered to have a cardiac cause of syncope until proven otherwise. Although the history, physical examination, electrocardiogram, and normal stress test and echocardiogram from 4 years earlier made a cardiac cause less likely in this patient despite his age, the patient was sent home with a 24-hour ambulatory electrocardiographic recording device and plans were made for an exercise treadmill test in the near future, given the relationship of his symptoms to exercise. Exercise stress testing is a particularly valuable part of the evaluation of patients with exertional syncope or near-syncope. The normal response to treadmill exercise is a progressive increase in systolic blood pressure and no change or a decrease in diastolic blood pressure; a drop of the systolic blood pressure during exercise below the standing pre-exercise value typically defines exercise-induced hypotension.⁶ Exercise-induced hypotension during treadmill testing often reflects left ventricular dysfunction or myocardial ischemia. When associated with either of these 2 factors, it indicates a significantly increased risk for cardiac events.⁶ Echocardiography to rule out structural heart disease was also considered in this patient, but was not performed as the initial diagnostic test because his echocardiogram was completely normal 4 years earlier and his physical examination and electrocardiogram were normal during the current evaluation.

The patient history is of critical importance in determining the cause of syncope and can often obviate the need for extensive diagnostic testing. The history, physical examination, and baseline electrocardiogram provide a diagnosis in 50% of patients with syncope.⁷ When approaching a patient like the man presented in this case, it is important to clarify the relationship of symptoms to exertion. Exertional syncope usually indicates one of the cardiac or cardiopulmonary causes shown in BOX 3.⁸ Left or right ventricular outflow tract obstruction and pulmonary hypertension produce effort syncope because in these conditions, cardiac output is unable to increase in response to the increased peripheral demand of exercise. This, coupled with the fall in peripheral resistance during exercise, may lead to effort syncope.⁹ However, in some circumstances, a patient with one of the conditions shown in Box 3 may have few or no symptoms during exercise if sympathetic tone increases sufficiently during effort to limit or prevent the fall in peripheral vascular resistance that ordinarily occurs at this time. Symptoms may then only begin after exertion, once the increase in sympathetic tone is withdrawn. Although a cardiac cause of syncope was initially suspected in this patient, significant cardiac or cardiopulmonary disease was considered very unlikely because of the complete absence of symptoms during exercise and his normal physical examination results.

Postexercise Hypotension

The patient presented in this case did not experience symptoms during exertion and only noted any problems after exercise. This initially suggested a diagnosis of PEH. Lightheadedness after exercise may be caused by hypovolemia or by antihypertensive medications; this can usually be easily identified by history. Postexercise hypotension is a condition that is caused by an abnormality in autonomic regulation of vascular tone or heart rate. Individuals with PEH develop a marked fall in peripheral vascular resistance immediately after moderate-intensity aerobic exercise^{10,11} that is

not completely offset by an increase in cardiac output. The hypotension that results may last several hours.^{12,13} The mechanism of the peripheral vasodilation occurring after exercise is not clear, although various factors have been implicated including impaired sympathetic vasoconstriction,^{14,15} resetting of the arterial baroreflex control of heart rate after exercise,¹⁶ and increased nitric oxide production.¹⁷

Less commonly, PEH may result from marked bradycardia or asystole after exercise in otherwise healthy individuals.¹⁸⁻²⁰ This appears to be due to a vasovagal reaction that relates to activation of the so-called Bezold-Jarisch reflex.²¹ During exercise, the vigorous contractions of an underfilled heart may initiate an inhibitory vasovagal reaction by stimulating ventricular mechanoreceptors whose nonmyelinated C-fibers carry afferent inputs to the medulla. The efferent response slows the heart rate and counteracts the sympathetic response by increasing parasympathetic neural input to the heart via the vagus nerve. After exercise and withdrawal of the sympathetic response, a person with this type of PEH may have significant slowing of the heart rate or asystole and lose consciousness.

Postexercise hypotension was an important consideration in this patient because of the constant and predictable relationship between the onset of his symptoms and the cessation of exercise, and because this diagnosis is more common in older individuals with chronic hypertension. However, there was a particular feature of this patient's near-syncope that was striking. After interviewing the patient again, the consistent temporal relationship of his symptoms to the act of taking his pulse after exercise became apparent. Just as striking was the absence of symptoms after exercise the day he wore the Holter monitor, when he did not take his pulse knowing that it was already being recorded by the device.

The patient was asked to demonstrate his recent severe episode that almost resulted in loss of consciousness. He began walking in place in the examining room

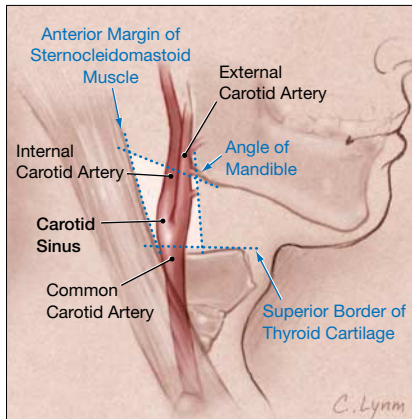
Box 3. Conditions Producing Effort Syncope

Left ventricular outflow tract obstruction
 Aortic stenosis
 Hypertrophic obstructive cardiomyopathy
 Right ventricular outflow tract obstruction
 Pulmonary valve stenosis
 Infundibular stenosis
 Pulmonary hypertension
 Arrhythmia
 Myocardial ischemia

as if on a treadmill, then stopped and immediately put his hand on his neck to check his pulse. He was asked to stop the demonstration. The patient was then asked to lie on the examining table and continuous electrocardiographic and blood pressure monitoring was initiated. After recording a rhythm strip, gentle carotid sinus pressure was applied by the examiner. This resulted in a 5-second ventricular pause. The patient said he felt the same way during this maneuver as he did after exercise. His blood pressure measured 15 seconds after initiation of the carotid sinus pressure was normal.

Carotid Sinus Hypersensitivity

The history and examination in this patient provided the diagnosis of carotid sinus hypersensitivity (CSH), which was first reported as a cause of syncope by Weiss and Baker more than 70 years ago.²² Carotid sinus hypersensitivity has been reported as the cause of syncope in 5.8% of patients in one study²³ and 14% in another.²⁴ These studies may overestimate the role of CSH as a cause of syncope and may more accurately reflect the prevalence of an abnormal response to carotid sinus massage (CSM) in patients with otherwise negative evaluations for syncope. The prevalence of CSH in patients with an abnormal response to CSM in whom the history reveals a close relationship between syncope or near-syncope and accidental pressure on the carotid sinus (as in the case presented herein) has been estimated at about 1%.²⁵ Carotid sinus hy-

Figure 1. Location of the Carotid Sinus

The carotid sinus is a small dilatation of the internal carotid artery immediately above the bifurcation of the common carotid artery that contains specialized sensory nerve endings sensitive to pressure or stretch. To perform carotid sinus massage, firm but gentle pressure is applied to the area at the midpoint between the angle of the mandible and the superior border of the thyroid cartilage along the anterior margin of the sternocleidomastoid muscle.

persensitivity may cause unexplained falls in older individuals. In one study of 26 consecutive patients older than 65 years who presented to an emergency department with unexplained falls (mean age, 79 years), the prevalence of an asystolic response to CSM was 46%.²⁶ In a larger study, CSH was found in 65 (23%) of 279 unexplained or recurrent fallers.²⁷ To determine the effective treatment for CSH, older patients with this condition were randomized to receive a dual-chamber permanent pacemaker or no pacing. Falls were reduced by two thirds in the group that received a pacemaker.²⁸ In another randomized study, 32 patients with symptomatic CSH received pacemakers and 28 did not. After an average follow-up of 3 years, syncope recurred in 9% of the pacing group, whereas it recurred in 57% of those who did not receive a pacemaker.²⁹

Syncope in patients with CSH is caused by pressure on the carotid sinus, a small dilatation of the internal carotid artery immediately above the bifurcation of the common carotid artery in which the adventitia contains a large number of sensory nerve endings that are sensitive to pressure or

stretch (FIGURE 1). Sensory impulses from these stretch receptors are carried via branches of the glossopharyngeal nerve to vasomotor and cardio-inhibitory centers in the medulla. Stimulation of these centers inhibits sympathetic impulses to peripheral blood vessels and increases vagal stimulation of the heart. A patient with CSH may experience lightheadedness or syncope when these stretch receptors are stimulated by abruptly turning the head, by wearing a tight collar, by shaving, or by compression or invasion of the carotid sinus or of the glossopharyngeal nerve by a head and neck tumor.

There are 2 types of CSH, each of which is related to the respective medullary center from which the efferent limb of the reflex originates (FIGURE 2). The vagal or cardioinhibitory type of CSH results from reflex slowing of the heart and may produce sinus arrest or asystole, as it did in the patient in this case. The other, known as the vasodepressor type of CSH, produces hypotension without bradycardia due chiefly to inhibition of sympathetic vasoconstriction. About one third of individuals with CSH demonstrate both responses.

Carotid Sinus Massage

Carotid sinus massage is recommended as part of the evaluation of patients older than 40 years who have syncope of unclear cause.¹ The procedure is contraindicated in individuals with an acute myocardial infarction or in a patient with a recent stroke or transient ischemic attack, known carotid artery occlusion, or with a history of a serious ventricular arrhythmia. Before considering CSM, the examiner should listen for a carotid bruit and if one is found, the maneuver should probably be avoided. For patients with a carotid bruit, some have recommended Doppler ultrasound prior to CSM to exclude critical stenosis³⁰ even though the risk of neurological complications resulting from the procedure is exceptionally low,³¹⁻³³ and significant carotid stenoses may still exist when no bruit is heard.³⁴

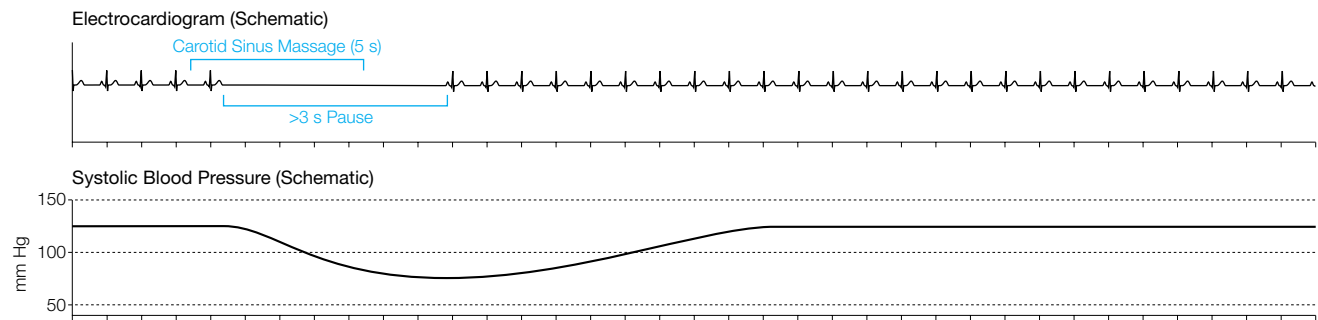
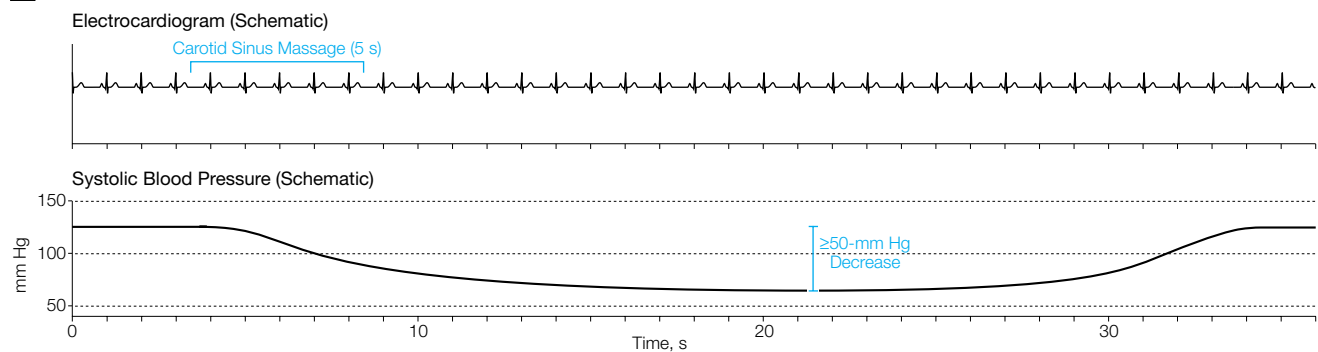
To perform CSM (BOX 4), the patient should lie supine for several minutes and

should be monitored continuously with an electrocardiogram and, ideally, with a blood pressure monitor that is capable of beat-to-beat recording. Two individuals should be present, one to evaluate the patient and perform CSM and the other to obtain the electrocardiogram and to record symptoms and blood pressure. It is recommended that a defibrillator and an advanced cardiac life support crash cart be available in the unlikely event that they will be needed.

The carotid sinus (initially on the right) should be identified at the midpoint between the angle of the mandible and the superior border of the thyroid cartilage right along the anterior margin of the sternocleidomastoid muscle (Figure 1). The area should be initially touched with firm but gentle pressure with careful attention to the electrocardiogram. This should be done even before massage is performed because some patients, as the man presented herein, have hypersensitivity of the carotid sinus that is evoked merely with gentle pressure. If a positive response (see below) does not result from this alone, the area should be massaged with a similar degree of pressure for about 5 seconds. All actions by the examiner should be marked on the electrocardiogram and the patient's symptoms should be recorded elsewhere. The blood pressure should be recorded within 15 seconds of CSM. A positive response is generally defined as a decrease in systolic blood pressure of 50 mm Hg or greater (vasodepressor response), a ventricular pause of more than 3 seconds (cardioinhibitory response), or a combination of these (mixed response). The diagnosis of CSH is enhanced if CSM elicits symptoms consistent with the diagnosis, even if the classic hemodynamic response is not obtained. Repeating CSM with the patient upright, typically using a tilt table, has also been recommended as a more useful procedure to evaluate the vasodepressor response to CSM.¹

CASE RESOLUTION

The patient underwent placement of a dual-chamber permanent pacemaker

Figure 2. Types of Responses to Carotid Sinus Massage in Carotid Sinus Hypersensitivity**A** Cardioinhibitory Response**B** Vasodepressor Response

A, A pure cardioinhibitory response produces a reflex slowing of the heart and may produce sinus arrest or asystole. A fall in systolic blood pressure typically occurs deriving from and proportional to the extent and duration of the decrease in heart rate. During carotid sinus massage, a positive cardioinhibitory response is defined as a ventricular pause of more than 3 seconds. If the slowing of the heart is prevented (for example with a pacemaker), individuals exhibiting a pure cardioinhibitory response will not experience a decline in blood pressure. B, A pure vasodepressor response produces hypotension without bradycardia due chiefly to inhibition of sympathetic vasoconstriction. A pure vasodepressor response results in a decline in systolic blood pressure that is of longer duration than that observed in a pure cardioinhibitory response. During carotid sinus massage, a positive vasodepressor response is defined as a decline in the systolic blood pressure of 50 mm Hg or greater. Note that about a third of individuals demonstrate both types of hypersensitivity responses.

and returned to regular treadmill exercise with no difficulty. It was suggested that he check his pulse in his wrist rather than his neck and that he drink water or an electrolyte solution before exercising to minimize dehydration. He has had no recurrent light-headedness or near-syncope now almost 2 years later. This is the expected outcome in a patient in whom the cardioinhibitory type of CSH predominates. Although many individuals with the cardioinhibitory type of CSH also have some vasodepressor symptoms and signs,³⁵ dual-chamber cardiac pacing is curative in the majority^{28,29} and is recommended for patients with recurrent syncope caused by carotid sinus stimulation in whom minimal carotid sinus pressure induces ventricular asystole of more than 3 seconds' dura-

Box 4. Carotid Sinus Massage**Who?**

Patients with unexplained syncope, especially those aged 40 years and older
Contraindicated if acute myocardial infarction, recent stroke or transient ischemic attack, history of ventricular fibrillation/ventricular tachycardia

How?

Patient should be supine and monitored continuously with an electrocardiogram
Two individuals are needed: one to massage, the other to record
A defibrillator and cardiac drugs should be in the room
Gently but firmly touch the carotid sinus (see text) for 5 seconds
If no response, massage carotid sinus for 5 seconds, no more than 10 seconds

What Is a Positive Response?

Positive response = decrease in systolic blood pressure ≥ 50 mm Hg, ventricular pause of >3 seconds, or both

tion.³⁶ Since pacing does not alter the vasodepressor response, those individuals with this type of CSH or who

have a mixed cardioinhibitory and vasodepressor response may need additional or alternative treatment. This may

be particularly likely in older women with CSH, since they appear to be at greatest risk of having a vasodepressor response.³⁵ There are no randomized studies examining the treatment of vasodepressor CSH and the therapy of this form of CSH is generally less satisfactory than the treatment of cardioinhibitory CSH. Vasodepressor CSH is often treated as is neurocardiogenic syncope with lower-limb compression, the alpha-adrenergic agonist midodrine, salt, or the mineralocorticoid fludrocortisone. Selective serotonin reuptake inhibitors have also been used in this condition.^{37,38}

Syncope, Near-Syncope, and the Clinical History

This patient highlights the importance of the clinical history in the evaluation of patients with syncope and near-syncope. Recently, Haidet and Paterniti discussed the distinction between “building” a history and “taking” one.³⁹ These authors emphasized the role of both the patient and the physician in the unfolding of the clinical history. One can effectively build a history by allowing the patient to demonstrate an action that reproducibly elicits symptoms; this may sometimes pinpoint the diagnosis. When evaluating a patient with syncope or near-syncope, one must allow the patient to tell, or at times to demonstrate, his or her “story,” sometimes with the help of a family member or witness to the event. This case also demonstrates the importance of revisiting the history when the diagnosis is not immediately apparent. The history may help the practitioner focus the physical examination, which should always include orthostatic blood pressure measurements, cardiac auscultation, and CSM in those older than 40 years. With this approach, along with the evaluation of an electrocardiogram, the diagnosis becomes apparent in many cases.

Acknowledgment: I thank my patient for sharing his story. I also thank the following individuals for their helpful comments: David B. Hellmann, MD, for his critical reading of the manuscript and Peter Kaplan, MD, for his review of the figures.

REFERENCES

1. Brignole M, Alboni P, Benditt D, et al, for the Task Force on Syncope, European Society of Cardiology. Guidelines on management (diagnosis and treatment) of syncope. *Eur Heart J*. 2001;22:1256-1306.
2. Kapoor WN, Karpf M, Wieand S, Peterson JR, Levey GS. A prospective evaluation and follow-up of patients with syncope. *N Engl J Med*. 1983;309:197-204.
3. Eagle KA, Black HR, Cook EF, Goldman L. Evaluation of prognostic classifications for patients with syncope. *Am J Med*. 1985;79:455-460.
4. Martin TP, Hanusa BH, Kapoor WN. Risk stratification of patients with syncope. *Ann Emerg Med*. 1997;29:459-466.
5. Kapoor W, Snustad D, Peterson J, Wieand HS, Cha R, Karpf M. Syncope in the elderly. *Am J Med*. 1986;80:419-428.
6. Froelicher VF. Interpretation of hemodynamic responses to the exercise test. In: Froelicher VF, ed. *Manual of Exercise Testing*. 2nd ed. St Louis, Mo: Mosby-Year Book Inc; 1994:45-48.
7. Linzer M, Yang EH, Estes NA 3rd, Wang P, Vorperian VR, Kapoor WN, for the Clinical Efficacy Assessment Project of the American College of Physicians. Diagnosing syncope, part 1: value of history, physical examination, and electrocardiography. *Ann Intern Med*. 1997;126:989-996.
8. Manolis AS, Linzer M, Salem D, Estes NA 3rd. Syncope: current diagnostic evaluation and management. *Ann Intern Med*. 1990;112:850-863.
9. Boudoulas H, Nelson SD, Schaaf SF, Lewis RP. Diagnosis and management of syncope. In: Fuster V, Alexander RW, O'Rourke RA, eds. *Hurst's The Heart*. 10th ed. New York, NY: McGraw-Hill; 2001:1003.
10. Cleroux J, Kouame N, Nadeau A, Coulombe D, Lacourciere Y. Aftereffects of exercise on regional and systemic hemodynamics in hypertension. *Hypertension*. 1992;19:183-191.
11. Halliwill JR, Taylor JA, Hartwig TD, Eckberg DL. Augmented baroreflex heart rate gain after moderate-intensity, dynamic exercise. *Am J Physiol*. 1996;270:R420-R426.
12. Kenney MJ, Seals DR. Postexercise hypotension: key features, mechanisms, and clinical significance. *Hypertension*. 1993;22:653-664.
13. Halliwill JR. Mechanisms and clinical implications of post-exercise hypotension in humans. *Exerc Sport Sci Rev*. 2001;29:65-70.
14. Floras JS, Sinkey CA, Aylward PE, Seals DR, Thoren PN, Mark AL. Postexercise hypotension and sympathetic inhibition in borderline hypertensive men. *Hypertension*. 1989;14:28-35.
15. Halliwill JR, Taylor JA, Eckberg DL. Impaired sympathetic vascular regulation in humans after acute dynamic exercise. *J Physiol*. 1996;495:279-288.
16. Somers VK, Conway J, LeWinter M, Sleight P. The role of baroreflex sensitivity in post-exercise hypotension. *J Hypertens Suppl*. 1985;3(suppl 3):S129-S130.
17. Legramante JM, Galante A, Massaro M, et al. Hemodynamic and autonomic correlates of postexercise hypotension in patients with mild hypertension. *Am J Physiol Regul Integr Comp Physiol*. 2002;282:R1037-R1043.
18. Osswald S, Brooks R, O'Nunain SS, et al. Asystole after exercise in healthy persons. *Ann Intern Med*. 1994;120:1008-1011.
19. Huycke EC, Card HG, Sobol SM, Nguyen NX, Sung RJ. Postexertional cardiac asystole in a young man without organic heart disease. *Ann Intern Med*. 1987;106:844-845.
20. Lowe MD, Petch MC. Syncope after effort. *Postgrad Med J*. 2000;76:164-165.
21. Mark AL. The Bezold-Jarisch reflex revisited: clinical implications of inhibitory reflexes originating in the heart. *J Am Coll Cardiol*. 1983;1:90-102.
22. Weiss S, Baker JP. The carotid sinus reflex in health and disease: its role in the causation of fainting and convulsions. *Medicine*. 1933;12:297-354.
23. Mathias CJ, Deguchi K, Schatz I. Observations on recurrent syncope and presyncope in 641 patients. *Lancet*. 2001;357:348-353.
24. Alboni P, Brignole M, Menozzi C, et al. Diagnostic value of history in patients with syncope with or without heart disease. *J Am Coll Cardiol*. 2001;37:1921-1928.
25. Brignole M. Randomized clinical trials of neurally mediated syncope. *J Cardiovasc Electrophysiol*. 2003;14:S64-S69.
26. Davies AJ, Steen N, Kenny RA. Carotid sinus hypersensitivity is common in older patients presenting to an accident and emergency department with unexplained falls. *Age Ageing*. 2001;30:289-293.
27. Richardson DA, Bexton RS, Shaw FE, Kenny RA. Prevalence of cardioinhibitory carotid sinus hypersensitivity in patients 50 years or over presenting to the accident and emergency department with “unexplained” or “recurrent” falls. *Pacing Clin Electrophysiol*. 1997;20:820-823.
28. Kenny RA, Richardson DA, Steen N, Bexton RS, Shaw FE, Bond J. Carotid sinus syndrome: a modifiable risk factor for nonaccidental falls in older adults (SAFE PACE). *J Am Coll Cardiol*. 2001;38:1491-1496.
29. Brignole M, Menozzi C, Lolli G, Bottoni N, Gaggioli G. Long-term outcome of paced and nonpaced patients with severe carotid sinus syndrome. *Am J Cardiol*. 1992;69:1039-1043.
30. O'Shea D, Parry SW, Kenny RA. The Newcastle protocol for carotid sinus massage. *J Am Geriatr Soc*. 2001;49:236-237.
31. Munro NC, McIntosh S, Lawson J, Morley CA, Sutton R, Kenny RA. Incidence of complications after carotid sinus massage in older patients with syncope. *J Am Geriatr Soc*. 1994;42:1248-1251.
32. Richardson DA, Bexton R, Shaw FE, Steen N, Bond J, Kenny RA. Complications of carotid sinus massage—a prospective series of older patients. *Age Ageing*. 2000;29:413-417.
33. Davies AJ, Kenny RA. Frequency of neurologic complications following carotid sinus massage. *Am J Cardiol*. 1998;81:1256-1257.
34. Davies KN, Humphrey PR. Do carotid bruits predict disease of the internal carotid arteries? *Postgrad Med J*. 1994;70:433-435.
35. Gaggioli G, Brignole M, Menozzi C, et al. Reappraisal of the vasodepressor reflex in carotid sinus syndrome. *Am J Cardiol*. 1995;75:518-521.
36. Gregoratos G, Abrams J, Epstein AE, et al, for the American College of Cardiology/American Heart Association Task Force on Practice Guidelines/North American Society for Pacing and Electrophysiology Committee to Update the 1998 Pacemaker Guidelines. ACC/AHA/NASPE 2002 guideline update for implantation of cardiac pacemakers and antiarrhythmia devices: summary article: a report of the American College of Cardiology/American Heart Association Task Force on Practice Guidelines (ACC/AHA/NASPE Committee to Update the 1998 Pacemaker Guidelines). *Circulation*. 2002;106:2145-2161.
37. Dan D, Grubb BP, Mouhaffel AH, Kosinski DJ. Use of serotonin re-uptake inhibitors as primary therapy for carotid sinus hypersensitivity. *Pacing Clin Electrophysiol*. 1997;20:1633-1635.
38. Grubb BP, Samoil D, Kosinski D, Temesy-Armos P, Akpunonu B. The use of serotonin reuptake inhibitors for the treatment of recurrent syncope due to carotid sinus hypersensitivity unresponsive to dual chamber cardiac pacing. *Pacing Clin Electrophysiol*. 1994;17:1434-1436.
39. Haidet P, Paterniti DA. “Building” a history rather than “taking” one: a perspective on information sharing during the medical interview. *Arch Intern Med*. 2003;163:1134-1140.